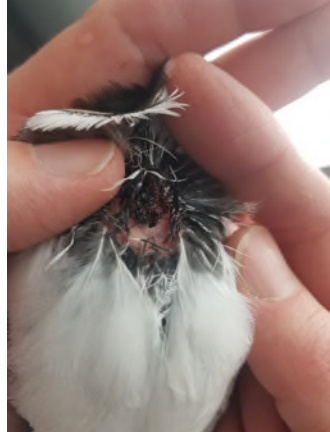


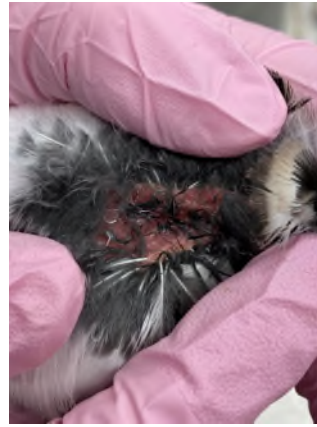Appendix 2: Photographs showing typical progression of wound healing following adipose biopsy procedure on Killdeer



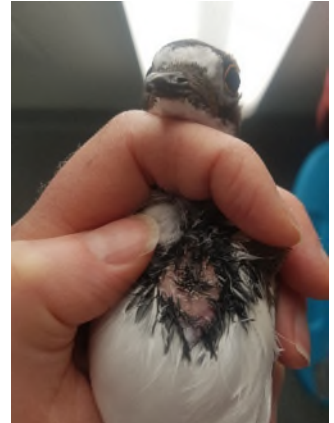
Application of Emla analgesic cream



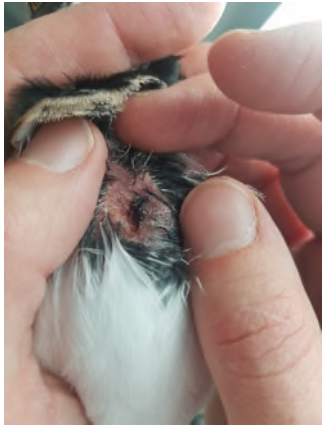Incision post biopsy



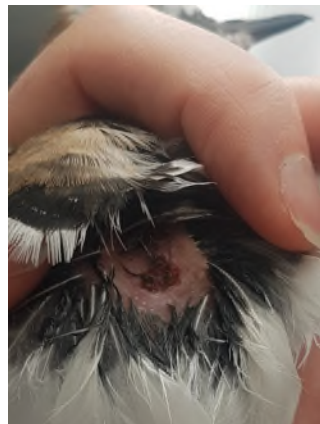
Biopsy site after application of Vetbond skin glue




Day 1 post surgery




Day 3 post surgery



Day 7 post surgery



Day 14 post surgery



Day 15-20 Fully healed